

# Results of centralized Asherman surgery, 2003–2013

Miriam M. F. Hanstede, M.D., Eva van der Meij, M.D., Laurien Goedemans, M.D., and Mark Hans Emanuel, M.D., Ph.D.

Department of Obstetrics and Gynaecology, Spaarne Ziekenhuis Hoofddorp, Hoofddorp, the Netherlands

**Objective:** To study the success rate of hysteroscopic adhesiolysis and the spontaneous recurrence rate of intrauterine adhesions (IUAs) in patients with Asherman syndrome.

**Design:** Cohort study.

**Setting:** University-affiliated hospitals.

**Patient(s):** A total of 638 women with Asherman syndrome were included, all diagnosed using hysteroscopy, and operated on between 2003 and 2013.

**Intervention(s):** Hysteroscopic adhesiolysis.

**Main Outcome Measure(s):** Hysteroscopic adhesiolysis was classified as successful if a normalization of menstrual blood flow occurred, along with a restored, healthy, cavity anatomy, free of adhesions, with hysteroscopic visualization of  $\geq 1$  tubal ostium. Recurrences of adhesions were diagnosed using hysteroscopy after an initial successful procedure.

**Result(s):** A first-trimester procedure preceded Asherman syndrome in 371 women (58.2%) and caused adhesions of grades 1–2A. In 243 (38.1%) women, a postpartum procedure caused IUAs of grades 3–5. The procedure was successful in 606 women (95%), and restoration of menstrual blood flow occurred in 97.8%; IUAs spontaneously recurred in 174 (27.3%) of these cases. High grades of adhesions were predictive of a higher chance of spontaneous recurrence of adhesions.

**Conclusion(s):** In 95% of women with Asherman syndrome, a healthy uterine cavity was restored with hysteroscopic adhesiolysis, in 1–3 attempts, with a 28.7% recurrence rate of spontaneous IUAs. (Fertil Steril® 2015;104:1561–8. ©2015 by American Society for Reproductive Medicine.)

**Key Words:** Intrauterine adhesions, Asherman syndrome, hysteroscopic adhesiolysis, adhesions, hysteroscopy, amenorrhea

**Discuss:** You can discuss this article with its authors and with other ASRM members at <http://fertilityforum.com/hanstedem-outcomes-asherman-surgery/>



Use your smartphone to scan this QR code and connect to the discussion forum for this article now.\*

\* Download a free QR code scanner by searching for "QR scanner" in your smartphone's app store or app marketplace.

Intrauterine adhesions (IUAs) or synechiae were first described in 1894, by Heinrich Fritsch, a highly regarded surgeon and teacher at the University in Bonn (1). In 1927, Bass (2) reported 20 cases of cervical obstruction, in 1,500 patients who had undergone induced abortions in a Russian hospital. In Copenhagen, in 1946, Stamer (3) described 24 cases of IUAs, both postpartum and after abortion. A Czech immigrant from Israel named Joseph G. Asherman, described in 1948

the frequency, etiology, and symptoms of IUAs. He defined 2 entities: traumatic IUAs; and stenosis of the internal cervical ostium (4–6). Since then, Asherman syndrome has been the term used to describe the disease.

Possible underlying causes of IUAs include a traumatic event to the uterine mucosa. Such an event is possible in either a gravid or nongravid uterus, but it is most frequent in a gravid uterus. Causes of adhesions in a gravid uterus include: miscarriages, with or

without curettage; postpartum curettage; postabortion or postpartum endometritis; ischemic phenomena after postpartum hemorrhage; and uterine artery embolization. For a nongravid uterus, much less common causes of IUAs include use of surgical hysteroscopy (resection or destruction of endometrium, myomas, polyps, and uterine septae), and infections, such as genital tuberculosis. Women with IUAs often struggle with infertility, menstrual irregularities (including amenorrhea, hypomenorrhea, and dysmenorrhea), recurrent pregnancy loss, and a history related to abnormal placentation, including previa and accreta (7).

The prevalence of IUAs varies enormously, depending on the population being studied, differences in definitions, and the various methods of diagnosis. Large geographic variation may

Received June 9, 2015; revised August 30, 2015; accepted August 31, 2015; published online October 1, 2015.

M.M.F.H. has nothing to disclose. E.v.d.M. has nothing to disclose. L.G. has nothing to disclose. M.H.E. has nothing to disclose.

Reprint requests: Miriam M. F. Hanstede, M.D., Department of Obstetrics and Gynaecology, Spaarne Gasthuis Hoofddorp/Haarlem, PO BOX 100 DD, 1100 DD Hoofddorp, the Netherlands (E-mail: [mhanstede@spaarneziekenhuis.nl](mailto:mhanstede@spaarneziekenhuis.nl)).

Fertility and Sterility® Vol. 104, No. 6, December 2015 0015-0282/\$36.00

Copyright ©2015 American Society for Reproductive Medicine, Published by Elsevier Inc. <http://dx.doi.org/10.1016/j.fertnstert.2015.08.039>

result from differences in several factors, including incidence of both illegal and legal abortion, techniques for puerperal and postabortion evacuation of retained products of conception, criteria for diagnosis of IUAs, awareness of clinicians, and incidence of puerperal infection and genital tuberculosis (8).

Asherman's rationalization was based primarily on a sequence of cases of IUAs that occurred after curettage of a gravid uterus.

Currently, some authors (8) feel that every instance of IUAs should be diagnosed as Asherman syndrome. We suggest that because of the differences in incidence, pathogenesis, etiology, treatment, and outcome of such unintended IUAs, vs. IUAs to the nongravid uterus, the term Asherman syndrome should be used exclusively in reference to women who have IUAs that were caused by unintended trauma to the endometrium in the gravid uterus.

In addition, the presence of symptoms is vital for the classification of Asherman syndrome. With the introduction of hysteroscopy that can be performed in a clinician's office, adhesions can be easily detected more frequently, but if they are not causing symptoms, they seem clinically irrelevant. Therefore, in our opinion, the definition of Asherman syndrome should be based on 2 criteria. The first is presence of IUAs caused by unintended trauma to the endometrium in the gravid uterus, diagnosed hysteroscopically. The second is  $\geq 1$  clinical feature resulting from a pregnancy-related intrauterine procedure or a pregnancy-related infection: amenorrhea; hypomenorrhea; subfertility; recurrent pregnancy loss; or a history related to abnormal placentation, including previa and accreta.

Hysteroscopy is the method of choice for the diagnosis and treatment of Asherman syndrome. Various techniques for adhesiolysis and prevention of scar reformation have been advocated (8). Surgical success may be defined by the restoration of healthy uterine anatomy, the restoration of healthy menses, and the spontaneous recurrence of IUAs after surgery. Another important outcome is fecundity after surgery for Asherman syndrome. The aim of the current study is to determine the success rate (restoration of healthy uterine cavity anatomy and healthy bleeding patterns) of hysteroscopic adhesiolysis in patients who have Asherman syndrome in a large cohort in which patients were centralized for diagnosis and treatment.

## MATERIALS AND METHODS

The study was approved by the national and local institutional review boards.

### Patients

Using an electronic patient database and logbooks of the operation theater, any patients that were scheduled for an hysteroscopic adhesiolysis because of IUAs were identified. The patients were included in the cohort if they were diagnosed as having Asherman syndrome, based on 2 criteria. The first was presence of IUAs caused by nonintended trauma to the endometrium in the gravid uterus, diagnosed hysteroscopically. The second criterion was  $\geq 1$  clinical features resulting from a pregnancy-related intrauterine procedure or a pregnancy-related infection: amenorrhea, hypomenorrhea,

subfertility, recurrent pregnancy loss, or a history related to abnormal placentation, including previa and accreta.

Of the 707 patients initially found in the database, 69 did not meet these criteria and were excluded. A total of 27 (3.8%) women had an endometrial ablation; and 14 (2.0%) and 2 (0.3%), respectively, had a hysteroscopic or abdominal myomectomy. Additional reasons for exclusion include: IUAs after insertion of an IUD in 1 (0.1%) case; cervical biopsy or polypectomy performed in 5 (0.7%) cases; 1 case of curettage performed for menorrhagia; and 8 cases in which the cause of IUAs was not otherwise specified. Six women (0.8%) had genital tuberculosis, and in 5 (0.7%) women, an intrauterine infection in a nongravid uterus caused the IUAs. Formation of adhesions or fibrosis after gynecologic surgery, of the types in these cases, is caused by removal (intentional or unintentional) or destruction of the basal layer of the endometrium, and/or hypoxia or infection. Because of the differing incidence, etiology, and prognosis, we decided to classify them as a different group (11, 12). This group is very small in the Netherlands.

**Setting and protocol.** All patients were operated on for IUAs, during the period 2003–2013, at the “Spaarne Ziekenhuis,” a university-affiliated (University of Amsterdam and Free University Amsterdam) training hospital in the Netherlands. For surgery to treat Asherman syndrome, our department is recognized as a center where gynecologists and general practitioners refer their patients, for either initial treatment or treatment after others have been unsuccessful.

Patients were first seen in the outpatient clinic. If a hysteroscopy was performed at the referral center, a hysteroscopic adhesiolysis in the operating room was scheduled immediately. If not, an office hysteroscopy was performed, to confirm the IUA diagnosis. After the adhesiolyses, a second-look hysteroscopy was performed 8–10 weeks after surgery in all patients. In the past 25 years,  $\geq 1,500$  patients were operated on by two surgeons (M.H.E. and the late K. Wamsteker, M.D.).

### Hysteroscopic Adhesiolysis

Transcervical (or hysteroscopic) adhesiolysis (TCA) has been used since the early 1990s. This method is a combination of operative hysteroscopy, with conventional instruments, and intraoperative fluoroscopy (9). The goal is to identify “blocked” areas of endometrium and open up parts of the uterine cavity behind or above adhesions that are obscured. Broome and Vancaillie (10) later described a similar method.

A major benefit of this technique is the assessment of tubal patency during the procedure as the indicator of proper anatomic restoration of the uterine cavity. Another benefit is early detection of a false route, or perforation. With use of a small (3-mm) telescope (Olympus), a continuous flow sheath (4.5–6.5 mm), and size 5–7 French forceps and scissors (Storz an Olympus), visualization is ensured, thereby preventing blind dilation throughout the procedure.

All treatments in our study were hysteroscopic, and all adhesiolyses were performed with fluoroscopic control. We used scissors or biopsy forceps, which are precision instruments used to dissect adhesions and leave vital endometrial

parts untouched. The use of electro-surgery is counterproductive; use of these conventional instruments avoids endometrial destruction by electrical energy. The distention medium was saline. A vaginoscopic cervical approach was used, without cervical dilation. We used an automatic pump to regulate the pressure.

To lower the chance of reformation of adhesions and recurrence of the syndrome, we placed an intrauterine device (IUD) when possible (after removal of the copper, and containing no levonorgestrel [Norplant; Leiras Oy]; levonorgestrel is a registered trademark of The Population Council, Inc.) at the end of the procedure, to prevent direct contact of the dissected surfaces. In addition, we gave hormonal treatment with adjunctive estrogens ( $E_2$ ) and progesterone, on a 40-day schedule that includes 2 withdrawal bleedings to stimulate regeneration of the endometrium and promote reepithelialization of the scarred surface. At the time of the second withdrawal bleeding, the IUD is removed, followed by a second-look hysteroscopy 2 weeks later.

## Procedures

Baseline characteristics (age, parity, menstrual pattern, symptoms, medical history, number of causal procedures, and extent of IUAs) were obtained from a database of patient-related information. Symptoms were divided into 4 groups (menstrual abnormalities [amenorrhea and hypomenorrhea]; fertility problems; both of these; and other [abnormal placentation, including previa and accreta]).

The procedures that caused the IUAs were categorized into 2 main groups. One of these was first-trimester procedures, which included dilation and curettage (D&C) for ongoing miscarriage, incomplete miscarriage, pregnancy termination, and hydatidiform mole.

A second group was postpartum procedures, which included D&C for retained products of conception, using conventional hysteroscopy, cold loop resectoscopic myomec-tomy, electrosurgery (hot loop; VersaPoint), or hysteroscopic morcellation. Manual or digital removal of placenta, embolization, and uterine compressive sutures were included in this group.

## Adhesiolyses

The adhesiolyses were divided into initial procedures and those for spontaneous recurrence. Up to 3 adhesiolyses were performed, as needed to achieve complete cavity restoration. Recurrence was defined as adhesions observed during a new hysteroscopy after a successful initial TCA. In some cases, a repeated sounding and minimal dilation of the cervical canal and internal ostium (up to 5 on the Hegar scale) were needed during menstruation, for several months, to ensure adequate menstrual flow. This procedure was performed in an outpatient setting, with Hegar dilators, and local anesthesia when necessary. A new TCA was needed in some cases.

## Classifications

Three people analyzed the operation reports, to minimize potential sources of bias. The adhesions were classified accord-

ing to the European Society for Gynaecological Endoscopy classification of IUAs. This scoring system was adopted from the classification developed for the former European Society for Hysteroscopy, by Wamsteker and De Block (13). A TCA was classified as successful if the following criteria were met: a normalization of menstrual blood flow and a restored healthy cavity anatomy, free of adhesions with hysteroscopic visualization of  $\geq 1$  tubal ostium. If adhesiolysis is severe, the cavity can be completely unrecognizable, and a tubal ostium can easily be overlooked during hysteroscopy. We did not attempt a second adhesiolysis in a normalized cavity (feasible for implantation of an embryo) if a hysteroscopic view showed only 1 tubal ostium in the first attempt.

## Statistical Analysis

Data are presented as number (n) with percentage (%). Statistical analysis was performed using the independent samples test, after checking for normality by the Kolmogorov-Smirnov test. A multivariate analysis was performed using logistic regression analysis to evaluate which variables have significantly influenced the success of TCA, the reoccurrence of adhesions. The analysis was performed using SPSS (SPSS, Inc, ver. 21.0). Nominal and ordinal variables with regard to subgroups were analyzed using  $\chi^2$  analysis and the Mann-Whitney *U* test, respectively. Univariate multivariate analysis were both performed using logistic regression analysis to evaluate which variables have significantly influenced the success of TCA and the reoccurrence of adhesions. The analysis was performed using SPSS (SPSS, Inc, ver. 21.0).

## RESULTS

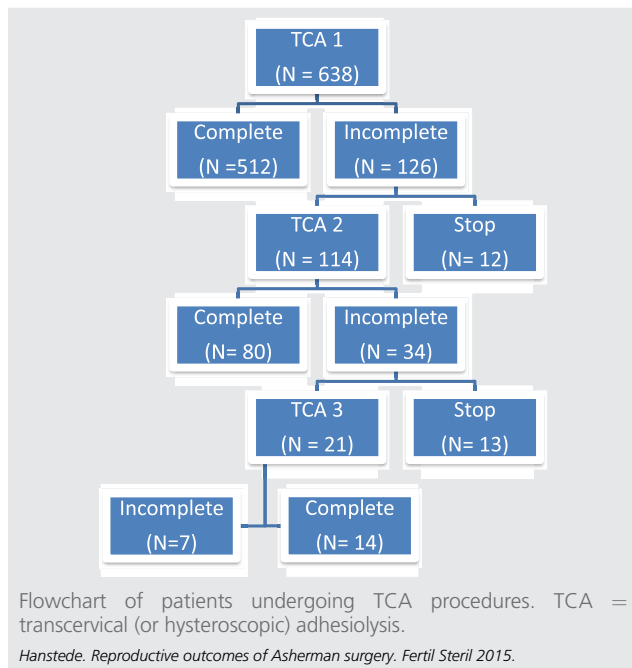
A total of 770 TCA procedures were performed in 638 patients. After the first adhesiolysis, a healthy uterine cavity was restored in 512 (80.3%) patients. However, in 46 of these, only 1 tubal ostium could be hysteroscopically visualized. A total of 126 (19.7%) patients had an incomplete adhesiolysis; of these, 114 had second procedures, and 12 refused a new attempt for various reasons. Eighty (70.2%) of the 114 patients having a second operation, had a successful second operation, with a restoration of the uterine cavity; in 19 of these, only 1 tubal ostium was visualized. After the second attempt, 34 (29.8%) patients still had an unfavorable outcome, with an unrestored uterine cavity. Of these patients, 13 denied further treatment for various reasons.

In the remaining 21 patients, a third procedure was performed in a final attempt to restore the uterine cavity. In 14 patients, this attempt was successful (66.7%); in the other 7 (33.3%), only 1 tubal ostium could be visualized (Fig. 1). The rate of perforation of the uterus was 16 of 638 (2.5%) in the first attempt; 4 of 114 (3.5%); and 1 of 21 (4.8%) in the third. No other complications, such as fluid overload or infection, were observed.

## Descriptive Data

The mean age of all patients was 34 years (range: 21–50 years, SD 4.30). Most patients (603 [94.5%]) had menstrual

**FIGURE 1**



abnormalities, such as, amenorrhea (64.4%) or hypomenorrhea (30.1%). In 44 (6.9%) cases, patients had primarily a fertility problem. A total of 276 (43.3%) patients had previously been pregnant 1 time; 362 (56.7%) had had ≥ 1 pregnancy at the time of diagnosis; and 320 (50.2%) had had ≥ 1 live birth.

In 99.8% of patients, Asherman syndrome was preceded by a pregnancy-related intra-uterine operative procedure. In >50% of all cases, this procedure was a first-trimester curettage for a miscarriage, a termination of pregnancy, or a molar pregnancy (n = 371 [58.2%]). In 243 (38.1%), a postpartum procedure caused the syndrome; in 23 (3.6%), a cesarean section was the origin of the IUAs. Only 1 patient (0.2%) had no surgery in her medical history; she had postpartum endometritis that presumably caused the syndrome (Table 1).

**Outcome**

At the “control” hysteroscopy, performed 2 months after initial surgery, patients’ menstrual pattern was evaluated. Of all 638 patients, a healthy pattern was restored in 624 (97.8%). Menses could not be restored (amenorrhea) in 14 (2.2%). A restored healthy cavity anatomy, free of adhesions, with hysteroscopic visualization of ≥ 1 tubal ostium was accomplished in 606 patients. Twenty-four patients refused a new attempt after incomplete or unsuccessful adhesiolysis. Therefore, the overall success rate (restoration of menses and cavity anatomy) was 95.0% (Table 2).

Subgroup analysis for first-trimester procedures (miscarriage, termination of pregnancy, and molar pregnancy) shows that in 373 patients, Asherman syndrome occurred in 239 (76.6%) patients after the initial curettage, and in 73

**TABLE 1**

**Baseline characteristics for 638 women, who underwent hysteroscopic adhesiolysis to treat Asherman syndrome.**

Characteristic	n (%)
Menstrual pattern before TCA	
Eumenorrhea	35 (5.5)
Hypomenorrhea	192 (30.1)
Amenorrhea	411 (64.4)
Symptoms	
Menstrual abnormalities	497 (77.9)
Infertility problems	44 (6.9)
Both	42 (6.6)
Other	55 (8.6)
Medical history	
Pregnancies (n)	
0	0 (0)
1	276 (43.3)
2	199 (31.2)
>2	163 (25.5)
Miscarriages (n)	
0	222 (34.8)
1	270 (42.3)
2	90 (14.1)
>2	56 (8.8)
Deliveries (n)	
0	215 (33.7)
1	320 (50.2)
2	88 (13.8)
>2	15 (2.4)
Causal procedures (n)	
First-trimester	371 (58.2)
Curettage after miscarriage	334
Termination of pregnancy	31
Hydatidform mole	6
Postpartum	243 (38.1)
Placental remnant curettage	179
Manual survey of the uterine cavity	20
Both	43
+ Uterine artery embolization postpartum	1
Cesarean section	23 (3.6)
None <sup>a</sup>	1 (0.2)
Grade of intrauterine adhesions found by first TCA attempt	
1	24 (3.8)
2	16 (2.5)
2A	211 (33.1)
3	226 (35.4)
4	107 (16.8)
5	54 (8.5)

Note: TCA = transcervical (hysteroscopic) adhesiolysis.  
<sup>a</sup> Postpartum endometritis.

*Hanstede. Reproductive outcomes of Asherman surgery. Fertil Steril 2015.*

(23.4%) patients after 2–7 curettages in a new pregnancy. Sixty-one patients developed the syndrome after a repeated curettage for persistent products of conception after initial curettage.

In 606 patients who had a successful TCA, 174 (28.7%) had spontaneous adhesion recurrence. Six (3.4%) women did not want a procedure to resolve these recurrent adhesions. In 42 patients (24.1%), the adhesions were mild enough that they could be removed during the outpatient hysteroscopy, with use of conventional instruments; and in 47 women (27.0%) by sounding and/or dilation of the isthmic area only. In 68 (39.1%) patients, 1 operative hysteroscopic adhesiolysis was needed to resolve these adhesions; in 11 (6.3%) women, 2 procedures were needed.

TABLE 2

Outcomes in 638 women treated for Asherman syndrome, with hysteroscopic adhesiolysis, in 1–3 attempts.

Outcome	n (%)
Effect on menstruation	
Resumption of menses	624 (97.8)
Amenorrhea	14 (2.2)
Adhesiolysis outcomes	
Successful	606 (95)
Incomplete	7 (1.2)
Drop out	25 (3.8)

Hanstede. Reproductive outcomes of Asherman surgery. Fertil Steril 2015.

The presence of spontaneous recurrence of adhesions was compared with the initial grade of adhesions. If the initial grade of adhesions was moderate, grade 1–2a, the chance of spontaneous recurrence of adhesion varied between 20.8% and 25.0%. Grade 3 had a recurrence rate of 29.1%, grade 4 38.5% and grade 5 41.9%. A multivariate analysis showed that apart from the grade of adhesions ( $P=.021$ ) age also significantly influences the chance of spontaneous recurrence of adhesions ( $P=.044$ ).

Patients with a first-trimester curettage were more prone to milder adhesions (grades 1, 2, and 2A). Patients with post-

partum problems had significantly more grades 3–5 adhesions (Fig. 2).

### Statistical Analysis

With the statistically significant variables obtained from the univariate analysis, a multivariate analysis was performed using logistic regression. This shows that only the grade of the adhesions has a significant influence on the success rate of TCA ( $P=.013$ ), after adjustment for parity, miscarriages, type of the causal procedure. Lower grades of adhesions have a positive prediction for success. For the multivariate analysis, grade of adhesions categorized in mild (grade 1, 2 and 2a) and severe (grade 3, 4 and 5) adhesions was used.

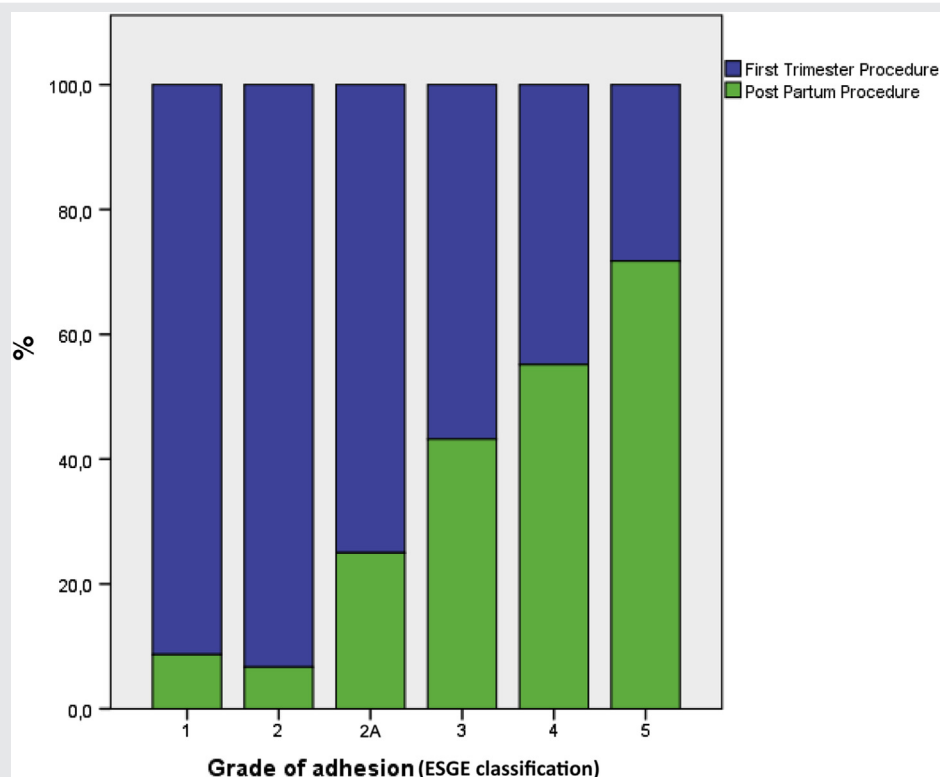
### DISCUSSION

To our knowledge, this study, with 638 patients, is the largest published series on outcome of hysteroscopic adhesiolysis for Asherman syndrome. In 95% of the women, a healthy uterine cavity was restored in 1–3 attempts; menses was restored in 97.8%.

### Interpretation

Compared with other series, this rate is high, especially given the relatively high number of severe cases (grades 3–5;

FIGURE 2



Adhesion grades, by procedure preceding Asherman syndrome. ESGE = European Society for Gynaecological Endoscopy.

Hanstede. Reproductive outcomes of Asherman surgery. Fertil Steril 2015.



60.7%). Only a few studies define normalization of the uterine cavity anatomy as successful outcome.

Fedele et al. reported in 1986, 31 cases of IUA, with 27 cases of complete adhesiolysis. After several months a repeat hystero-graphy and hysteroscopy was performed and showed complete normalization of the uterine cavity in 62.5% (14). Pace et al. reported in 2003 anatomic normalization of the cavity in 70 out of 75 (93.3%) patients after surgery in AS (15). Fernandez et al. reported in 2006, 71 cases with stage 3 and 4 AS; Reconstruction of a healthy uterine cavity was achieved in 31 (43.7%) cases after the first attempt (16). Capella and Allouc reported in 1999 about patients with severe intra uterine adhesions and in 51.6% of the 31 cases they described complete restoration of the cavity (17).

Most groups report on whether or not a menstruation was achieved after hysteroscopic treatment of intrauterine adhesions. In our study we find a 97.8% restoration of menses. From 1986 onwards studies were published with success rates ranging from 67.7% to 96%, defined as returning of healthy or improved menses after surgery, in series of 21–169 patients (13,18–22). The first study from Fedele et al. from 1986 reported on 21 cases with a success rate of 67.7%. Valle and Sciarra et al. described in 1988 169 patients, they had a success rate of 88.2%. Pabuccu et al. reported in 1997 on 34 cases and their success rate was 81%. In 2000 Preutthipan et al. described 73 cases, with a success rate of 90.9%. In 2004 Zikopoulos et al. reported on 46 cases with a success rate 92.4%. Yasmin in 2007 describes that in 96% of the 20 patients had their usual menstrual cycle returned after hysteroscopic adhesiolysis. In 2007 Thomson et al. describe a success rate of 81.5% in 30 cases. The latest publication from Robinson et al. in 2008 reported on 24 cases of which 95% had improvement of menstrual flow (Supplemental Table 1).

Because AS is a rare disease and adhesiolysis is difficult hysteroscopic procedure and because inadequate AS surgery is a serious threat for fertility, centralization is important. Centralization in AS surgery is not only essential because of the volume-outcome relationship but also because of improving support of women with AS, education, awareness and advocacy.

The high success rate achieved in this study can be explained by centralization of AS care. We have a relatively long experience of approximately 25 years of AS care and a concentration of expertise. The Netherlands is a small country of 37.354 km<sup>2</sup> with a high population of almost 17 million people (density 450/km<sup>2</sup>). Travel distances are relatively short and therefore centralization of difficult cases is easy and common.

The success rate of the first attempt was 80.3%, in the second attempt 70.2% and in the third procedure we were successful 66.7%. Therefore the number of hysteroscopic procedures envisioned treating, AS should not be a limited to one even if success rates after succeeding attempts are declining. This is consistent with finding in the literature (23).

We used fluoroscopic control but there are different modalities for control in this type of surgery such as laparoscopy or ultrasound. There is no golden standard nor is there any evidence that one method is superior to the other. The benefit of fluoroscopy in our experience is that it identifies 'blocked'

areas of obscured endometrium behind or above adhesions (10). A further benefit of this technique is the assessment of tubal patency during the procedure, as it is one of the landmarks of a proper anatomical restoration of the uterine cavity. Besides, a false route or perforation can be detected earlier. Our complication (perforation) rate varied between 2.5% in the first attempt to 4.8% in the third attempt, this is a lower than reported in the literature (17). The low complication rate could be contributed by the fluoroscopic control.

Repeated curettages are often mentioned as a high risk for the occurrence of AS (24, 25). It is important to distinguish between a repeated curettage because of a new pregnancy or a repeated curettage because of retained products in the same pregnancy (26). Of all our patients who had a first trimester curettage, more than three quarter developed AS after their first curettage only. Furthermore we noticed that patients with more than one miscarriage in their medical history had less severe adhesions. This might suggest that a personal (constitutional) vulnerability of (thin) endometrium could be more responsible for developing AS after pregnancy related intra uterine surgery than the procedure itself or the technique that was used in such procedures.

Patients with a first trimester curettage in their medical history had a better chance of a successful TCA than patients with post partum procedures. The last are more prone to cause more severe adhesions (grade 3, 4, and 5) and therefore lower the chance of a successful TCA. Furthermore they have a higher chance of spontaneous recurrence of IUA. We advocate that post partum remnants should be carefully approached and if possible hysteroscopic techniques should be used instead of blind curettages in order to minimize the damage to the uterus. Especially hysteroscopic morcellation techniques seem to be favorable in preventing the formation of adhesions in the uterine cavity (27).

Because of the high rate of spontaneous adhesion reformation in our study (27.3%) and in the literature (20%–62.5%) (28, 29), measures to prevent recurrences of adhesions are important.

We used a two-step method to prevent and reduce post surgical recurrence of IUA by placing an IUCD (often after removal of the copper or levonorgestrel) and a therapy of adjuvant hormones. Already in 1964 Wood and Pena described estrogen therapy to stimulate regeneration of the endometrium and improve its re-epithelialization (30). A control second-look hysteroscopy was performed in our setting two months after surgery. If opposed endometrial surfaces were 'adhered' during control hysteroscopy and the uterine cavity could be distended easily by the irrigation fluid or by the passage of the hysteroscope sheath only, they were not classified as recurred adhesions. If such filmy and minimal adhesions had been included however, the recurrence rate would be as high as 35%. Different techniques are described for the (secondary) prevention of adhesions: postoperative placement of IUCD's or (special) foley balloon catheters, anti-adhesive agents and adjuvant hormonal treatment are the most mentioned and used options. One retrospective study suggests that the intrauterine balloon and IUD are more effective in preventing intrauterine adhesion reformation than the use of hyaluronic acid gel (31). Randomised

control trials are needed to confirm the relative efficacy of these modalities in the prevention of intrauterine adhesions following treatment for AS.

We just started a randomized trial to confirm the efficacy of adjuvant estrogen treatment on the reduction of the recurrence of adhesions. We hope to report the findings in near future.

Studies on reproductive outcome after hysteroscopic adhesiolysis for AS are published since 1978. The most robust outcome of a successful adhesiolysis is life birth, since the untreated condition often leads to sterility. Reports on life birth after AS surgery are limited and numbers are small. The number of life births after successful adhesiolysis varies from 15% to 60% (14). We are currently completing the numbers and outcome of pregnancies and deliveries by a systematic large lifetime follow-up investigation that was approved by the local Institutional Review Board. We hope to report the results of this evaluation in the near future too.

### Limitations

Generalization of these results is potentially limited by the fact that all surgery was performed by a few surgeons, in 1 hospital, and the same surgeon who did the adhesiolysis often performed the second-look hysteroscopy. To limit this potential bias, we used very strict definitions.

### CONCLUSIONS

In conclusion, our findings show that most women with Asherman syndrome can successfully undergo hysteroscopic healthy uterine cavity eventually with resumption of menses (95%) but that the real challenge is to keep the cavity open because of high spontaneous recurrence of adhesions (27.3%).

Future research should be focused on diminishing the spontaneous recurrence rate by demonstrating the effect of preventive (adjuvant) measures preferably in randomised controlled trials. Since high grades of adhesions have a negative prediction for success and a higher chance of spontaneous recurrence of adhesions, it will be important for future research to determine the best way to approach post partum remnants, because they cause more severe IUA.

We strongly advocate centralization of Asherman surgery to reach higher volumes and to improve success rates and outcome. Furthermore, centralizing the care for patients with AS could stimulate the research for optimal care by randomised clinical trials that do not suffer from lack of recruitment caused by low volume of patients per centre.

**Acknowledgments:** The authors thank the Department of Obstetrics and Gynaecology at Spaarne Ziekenhuis.

### REFERENCES

- Fritsch H. Ein Fall von volligen Schwund der Gebärmutterhöhle nach Auskratzung. *Zentralbl Gynakol* 1894;18:1337–42.
- Bass B. Ueber die Verwachsungen in der cervix uteri nach curettagen. *Zentralbl Gynakol* 1927;51:223.
- Stamer S. Partial and total atresia of the uterus after excochleation. *Acta Obstet Gynecol Scand* 1946;26:263–97.
- Asherman JG. Amenorrhoea traumatica (atretica). *J Obstet Gynaecol Br Emp* 1948;55:23–30.
- Asherman JG. Traumatic intrauterine adhesions. *J Obstet Gynaecol Br Emp* 1950;57:892–6.
- Asherman JG. Traumatic intrauterine adhesions and their effects on fertility. *Int J Fertil* 1957;2:49–54.
- Yu D, Wong YM, Cheong Y, Xia E, Li TC. Asherman syndrome—one century later. *Fertil Steril* 2008;89:759–79.
- Schenker JG, Margalioth EJ. Intrauterine adhesions: an updated appraisal. *Fertil Steril* 1982;37:593–610.
- Wamsteker K. Intrauterine adhesions (synechiae). In: Brosens I, Wamsteker K, editors. *Diagnostic imaging and endoscopy in gynecology*. London: WB Saunders; 1997:171–84.
- Broome JD, Vancaillie TG. Fluoroscopically guided hysteroscopic division of adhesions in severe Asherman syndrome. *Obstet Gynecol* 1999;93:1041–3.
- Malhotra N, Bahadur A, Kalaivani M, Mittal S. Changes in endometrial receptivity in women with Asherman's syndrome undergoing hysteroscopic adhesiolysis. *Arch Gynecol Obstet* 2012;286:525–30.
- Papoutsis D, Georgantzis D, Daccò MD, Halmos G, Moustafa M, Mesquita Pinto AR. A rare case of Asherman's syndrome after open myomectomy: sonographic investigations and possible underlying mechanisms. *Gynecol Obstet Invest* 2014;77:194–200.
- Wamsteker K, De Block S. Diagnostic hysteroscopy: technique and documentation. In: Sutton C, Diamond M, editors. *Endoscopic surgery for gynecologists*. London: WB Saunders; 1998:511–24.
- Fedele L, Vercellini P, Viezzoli T, Ricciardiello O, Zamberletti D. Intrauterine adhesions: current diagnostic and therapeutic trends. *Acta Eur Fertil* 1986;17:31–7.
- Pace S, Stentella P, Catania R, Palazzetti PL, Frega A. Endoscopic treatment of intrauterine adhesion. *Clin Exp Obstet Gynecol* 2003;30:26–8.
- Fernandez H, Al Najjar F, Chauvenaud-Lambling A, Frydman R, Gervaise A. Fertility after treatment of Asherman's syndrome stage 3 and 4. *J Minim Invasive Gynecol* 2006;13:398–402.
- Capella-Allouc S, Morsad F, Rongieres-Bertrand C, Taylor S, Fernandez H. Hysteroscopic treatment of severe Asherman's syndrome and subsequent fertility. *Hum Reprod* 1999;14:1230–3.
- Valle RF, Sciarra JJ. Intrauterine adhesions: hysteroscopic diagnosis, classification, treatment, and reproductive outcome. *Am J Obstet Gynecol* 1988; 158:1459–70.
- Zikopoulos K. Live delivery rates in subfertile women with Asherman's syndrome after hysteroscopic adhesiolysis using the resectoscope or the Versapoint system. *Reprod Biomed Online* 2004;8:720–5.
- Yasmin H, Nasir A, Noorani KJ. Hysteroscopic management of Asherman's syndrome. *J Pak Med Assoc* 2007;57:553–5.
- Thomson AJ, Abbott JA, Kingston A, Lenart M, Vancaillie TG. Fluoroscopically guided synechiolysis for patients with Asherman's syndrome: menstrual and fertility outcomes. *Fertil Steril* 2007;87:405–10.
- Robinson JK, Swedarsky Colimon LM, Isaacson KB. Postoperative adhesiolysis therapy for intrauterine adhesions (Asherman's syndrome). *Fertil Steril* 2008;90:409–14.
- Fernandez H, Peyrelevade S, Legendre G, Faivre E, Deffieux X, Nazac A. Total adhesions treated by hysteroscopy: Must we stop at two procedures? *Fertil Steril* 2012;98:980–5.
- Hooker AB, Lemmers M, Thurkow AL, Heymans MW, Opmeer BC, Brölmann HA, et al. Systematic review and meta-analysis of intrauterine adhesions after miscarriage: prevalence, risk factors and long-term reproductive outcome. *Hum Reprod Update* 2014;20:262–78.
- Westendorp IC, Ankum WM, Mol BW, Vonk J. Prevalence of Asherman's syndrome after secondary removal of placental remnants or a repeat curettage for incomplete abortion. *Hum Reprod* 1998;13:3347–50.
- Nappi C, Di Spiezo Sardo A, Greco E, Guida M, Bettocchi S, Bifulco G. Prevention of adhesions in gynaecological endoscopy. *Hum Reprod Update* 2007;13:379–94.
- Hamerlynck TW, Blikkendaal MD, Schoot BC, Hanstede MM, Jansen FW. An alternative approach for removal of placental remnants: hysteroscopic morcellation. *J Minim Invasive Gynecol* 2013;20:796–802.

28. Preutthipan S, Linasmita V. Reproductive outcome following hysteroscopic lysis of intrauterine adhaesions: a result of 65 cases at Ramathibodi Hospital. *J Med Assoc Thai* 2000;83:42–6.
29. Pabuccu R, Atay V, Orhon E, Urman B, Ergun A. Hysteroscopic treatment of intrauterine adhesions is safe and effective in the restoration of normal menstruation and fertility. *Fertil Steril* 1997;68:1141–3.
30. Wood J, Pena G. Treatment of traumatic uterine synechias. *Int J Fertil* 1964; 9:405–10.
31. Lin X, Wei M, Li TC, Huang Q, Huang D, Zhou F, et al. A comparison of intrauterine balloon, intrauterine contraceptive device and hyaluronic acid gel in the prevention of adhesion reformation following hysteroscopic surgery for Asherman syndrome: a cohort study. *Eur J Obstet Gynecol Reprod Biol* 2013;170:512–6.



## SUPPLEMENTAL TABLE 1

**Study outcomes on restoration of healthy uterine anatomy and resumption of healthy menstrual pattern after surgery for Asherman syndrome.**

<b>First author and reference</b>	<b>Year</b>	<b>N</b>	<b>Successful restoration of healthy uterine anatomy (%)</b>
Fedele (14)	1986	21	62.5
Capella-Allouc (17)	1999	31	51.6
Pace (15)	2003	75	93.3
Fernandez (16)	2006	71	43.6
			<b>Healthy menstrual pattern restored (%)</b>
Fedele (14)	1986	21	67.7
Valle (18)	1988	169	88.2
Pabuccu (29)	1997	34	81.0
Preutthipan (28)	2003	65	90.9
Zikopoulos (19)	2004	46	93.4
Yasmin (20)	2007	20	96.0
Thomson (21)	2007	30	81.5
Robinson (22)	2008	24	95.0

*Hanstede. Reproductive outcomes of Asherman surgery. Fertil Steril 2015.*